

Using imaging biomarkers to accelerate drug development and clinical trials

Homer H. Pien, Alan J. Fischman, James H. Thrall and A. Gregory Sorensen

There is increasing evidence that human medical imaging can help answer key questions that arise during the drug development process. Imaging modalities such as magnetic resonance imaging, computed tomography and positron emission tomography can offer significant insights into the bioactivity, pharmacokinetics and dosing of drugs, in addition to supporting registration applications. In this review, examples from oncology, neurology, psychiatry, infectious diseases and inflammatory diseases are used to illustrate the role imaging can play. We conclude with some remarks concerning new developments that will be required to significantly advance the field of pharmaco-imaging.

▶ Remarkable progress in drug discovery and health-care innovation has been made in the past decade, providing relief and benefiting millions of patients. Such advances, however, come with a high cost – the development of new drugs represents a formidable undertaking requiring nearly one billion US dollars and 12 years to bring the average drug to commercialization [1]. Many have suggested the use of biomarkers as a method for obtaining early indications of drug effectiveness and safety, for both research and regulatory approval purposes, and thereby reducing cost and development time [2,3]. Such suppositions are not without basis. It has been shown that small improvements in clinical trial outcomes and decision-making translate into hundreds of millions of dollars of development cost-savings and a faster time-to-market [4]. Indeed, the use of biomarkers is sufficiently pervasive that they are routinely collected as part of many new drug trials.

The traditional gold standard for evaluating drug and device safety and efficacy is the prospective, randomized, well controlled, double-blind study [5]. Although this paradigm has served the public well in ensuring that new drugs and devices are thoroughly and scientifically evaluated before reaching

the consumer, some have argued that reliance on morbidity and mortality data – the so-called ‘true endpoints’ – could have had the unintended consequence of contributing to the high cost of pharmaceutical innovations. Recognizing this dilemma, in 1992, the US Food and Drug Administration (FDA) added provisions for accelerated approvals for drugs intended for serious or life-threatening diseases [6]. With enactment of the FDA Modernization Act of 1997, the FDA was given explicit authority to approve drugs for the ‘treatment of a serious or life-threatening condition...upon a determination that a product has an effect on a clinical endpoint or on a surrogate endpoint that is reasonably likely to predict clinical benefit’ [7].

One indication of the acceptance of surrogate endpoints is found in a recent survey of oncology drug approvals by the FDA. Of the 57 oncology drugs approved for marketing during the period of 1990–2002 and included in the study, only 18 relied upon traditional survival data. Of the additional 14 drugs that gained accelerated approvals, none relied upon traditional survival data [6]. Thus, the clinical trials of 53 out of 71 oncology drugs used surrogate endpoints, the most common one being tumor

Homer H. Pien*
Alan J. Fischman
James H. Thrall

A. Gregory Sorensen
Department of Radiology,
Massachusetts General
Hospital,
55 Fruit Street,
Boston,
MA 02114, USA
*e-mail:
hpien@nmr.mgh.harvard.edu

response – the change in tumor size [typically measured by magnetic resonance (MR) or computed tomography (CT) imaging] as a result of the drug therapy. It is evident that biomarkers in general, and imaging biomarkers in particular, have a solid foothold in the regulatory approval arena, especially in oncology*.

The use of imaging biomarkers for the assessment of drug therapies – a field termed here as ‘pharmaco-imaging’ – has become more common in recent years. Not surprisingly, the rise in use of pharmaco-imaging methodologies has coincided with the enormous technical advances that have occurred in medical imaging, especially in the non-invasive *in vivo* imaging modalities such as CT, MRI [8,9] and positron emission tomography (PET) [10,11].

Biomarkers such as analytes quantified from serum levels have been used for decades in the practice of medicine and in drug development. However, a range of new biomarkers, from imaging to genomics, have recently attracted interest. Several characteristics of imaging biomarkers set them apart from molecular, including genomic and proteomic, biomarkers. First, non-invasive imaging has been in routine use for diagnosis and disease management for several decades, and the ability to identify a wide spectrum of pathophysiology using imaging methods is well established. Second, imaging biomarkers tend to be much more closely associated with the expressed phenotype of diseases, thus enabling direct associations between therapy and effect. Third, imaging offers tremendous versatility for providing continuous, structural and functional assessments of therapy, offering snapshots of the bioactivity of drug compounds over time. Fourth, imaging provides therapy assessments in animals and humans alike, and is therefore an important tool for promoting translational research.

Despite the long history of medical imaging, its application to the drug development process is relatively recent. Therefore, this review aims to convey, using anecdotal examples, some of the ways in which imaging addresses issues arising from drug development. In particular, the focus is on new insights derived from imaging, rather than being exhaustive about the range of imaging applications to drug development.

Information from imaging

Imaging yields rich datasets from which several drug development questions could be addressed. Of course, no single imaging modality can answer all possible drug development questions. Indeed, a significant challenge in pharmaco-imaging is an understanding of the appropriateness of particular imaging options for addressing specific questions. While a full review of imaging is beyond

the scope of this article, some background material might be useful to place the techniques in context.

Computed tomography

X-ray radiography is the oldest form of *in vivo* imaging and continues to be an important area of medical imaging. X-ray radiation also forms the cornerstone of CT imaging, in which x-rays are emitted from a source and received by a set of detectors on the opposing side of the object. The source and detectors revolve around the patient continuously while the patient lies on a robotically controlled gantry. The resulting spiral CT scan is processed through interpolation and back-projection algorithms to form a series of cross-sectional images which, taken together, form a three-dimensional dataset representing the object of interest.

CT offers high resolution and fast acquisition of data, and is suited for studies that require precise characterizations of bony structures, such as the spine, or for cases in which image acquisition duration is of crucial importance, such as trauma. High-resolution CT is also preferred for characterizing lesions and other abnormalities within the chest and vascular structures, as well as many applications within the gastrointestinal and genitourinary regions. In the context of drug development, CT is a valuable tool for quantifying lesion size and location, particularly within the chest and abdominal regions. The image resolution of CT is >0.5 mm. More recently, by tracking the appearance of contrast-enhancing dyes as they wash into an organ, CT perfusion has gained greater applicability and utility [12].

Magnetic resonance imaging

In contrast to the use of ionizing radiation in CT, MRI uses radio-frequency pulses and magnetic fields to obtain signals from changes in nuclear magnetic moments. Specifically, as the alignment and relaxation of protons occur in response to pulsed radio-frequencies, characteristic relaxation times can be measured, most notably T_1 (the longitudinal relaxation time) and T_2 (the transverse relaxation time) (see, for example, Ref. [13]). Whereas CT images are characterized by a single parameter, namely the x-ray attenuation of the tissue along the propagation path, MRI is characterized by far more parameters, including proton density, T_1 , T_2 , flow, diffusion and susceptibility, among others [12]. It is this flexibility that makes the use of MRI a double-edged sword. MRI is useful in numerous applications, but repeatability and standardization in multi-center clinical trials can be challenging.

Although lower in resolution and requiring more time for data acquisition than that by CT, MRI offers superior soft tissue contrast, making MRI the modality of choice in the brain, in addition to specific applications in musculoskeletal and gastrointestinal systems. MRI, with and without contrast agents, is also used for numerous functional assessments, including tissue perfusion, diffusion, tumor

*Throughout this review, we refer to biomarkers as any observable physiological parameter, and refer to surrogate endpoints as those biomarkers that are proxies for clinically meaningful endpoints and are sufficiently well validated to be useful for regulatory approval purposes.

TABLE 1.

Physical characteristics of radionuclides used in PET imaging^a

Radionuclide	Half-life	Common forms
¹⁵ O	2 min	¹⁵ O ₂ , C ¹⁵ O ₂ , C ¹⁵ O
¹³ N	10 min	¹³ NH ₃ , ¹³ N ₂
¹¹ C	20 min	¹¹ CO ₂ , ¹¹ CO, ¹¹ CH
¹⁸ F	1.8 h	¹⁸ F ₂ , H ¹⁸ F
⁷⁶ Br	16.2 h	⁷⁶ Br ₂
¹²⁴ I	4 days	Na ¹²⁴ I

^aTable is adapted from Ref. [66].

permeability, and blood oxygenation level-dependent (BOLD) fMRI studies (see, for example, Refs [14,15]). A technique based on the same principle as MRI, but providing a greater degree of molecular characterization is magnetic resonance spectroscopy (MRS), where spectroscopic profiles of the chemical constituents within a sample are obtained [16].

Radionuclide imaging

The basis of radionuclide imaging is the use of bi-functional agents containing a radiolabel that confers detectability, and a chemical and/or pharmaceutical moiety that determines uptake and distribution in the body. In the case of positron-emitting radioisotopes, the emitted positron passes through tissue and is ultimately annihilated when combined with an electron, resulting in two 511 keV photons emitted in opposite directions. Detectors are arranged in a ring around the tissue of interest, and only triggering events that arrive near-simultaneously at diametrically opposite detectors are recorded [17]. Tomographic methods are then used to produce the resulting PET images.

Numerous radioisotopes are used for nuclear imaging. These tracer isotopes can be substituted into drug compounds directly to mimic naturally occurring compounds or can be complexed with other molecules to form new compounds referred to as radiopharmaceuticals. 2-¹⁸F-fluoro-2-deoxy-D-glucose (FDG), for example, is an analogue of glucose labeled with a positron-emitting form of fluorine and is used in PET imaging of metabolic activities that involve glucose uptake [11] (see Table 1 for examples of useful positron-emitters for PET imaging).

To summarize, we are witnessing a shift in imaging capabilities from purely anatomical structure to one that involves function and molecular specificity. It is this diversity in imaging capabilities that allows imaging biomarkers to address a spectrum of drug development issues.

Surrogate endpoint failure modes

Although the use of surrogate endpoints and imaging biomarkers holds great promise, it is important to remember that false conclusions can be reached if caution is not properly exercised. One notable example is the undue reliance on suppressing ventricular dysrhythmia determined from electrocardiograms for the development and approval

of anti-arrhythmia drugs, the result of which is the marketing of drugs that were later found to cause mortality at two to two and a half times higher than that of the placebo group [18–20].

When biomarkers fail, they can generally be classified into five failure modes, depending on the characteristics of the pathophysiological pathways, in addition to the relationship between these pathways and the purported biomarkers [2,19]. These failure modes are: (i) the biomarker is not in the disease pathophysiological pathway; (ii) the biomarker is not in the only pathophysiological pathway (i.e. several such pathways are present); (iii) the biomarker is not in the pathway affected by the therapeutic intervention; (iv) the intervention acts through different and potentially unknown pathways; and (v) the biomarker does not correlate well with traditional clinical endpoints because it is more sensitive than these traditional endpoints.

To illustrate, consider the rate of tumor size changes as a biomarker. In a meta-analysis of colorectal patients, it was found that the correlation coefficient between tumor response and survival is only 38% [21], indicating that other factors confound the relationship between tumor response and survival [i.e. failure mode (ii)].

By examining these failure modes, the characteristics of desirable biomarkers become apparent: proper understanding of the relationship between disease and the affected pathophysiological pathways must exist, and there must be sufficient validation to ensure that the biomarker (or a set of biomarkers) fully captures the effects on these pathways and on the relevant clinically meaningful endpoints.

Imaging for pre-clinical studies

Molecular imaging, using a variety of targeted probes and spanning optical MR and PET methods, provides insights into target validation and disease mechanism issues that are crucial in pre-clinical studies [11,22–26]. More-traditional imaging modalities, such as MRI, have also seen an increase in popularity in animal studies [9,27,28]. These pre-clinical studies take place in the context of high attrition rates for candidate pharmaceuticals when translating to human subjects, perhaps as a result of inadequate animal models of human pathophysiology [29,30]. Ultimately, it is anticipated that greater use of imaging during pre-clinical stages will facilitate better translation from animal models to human subjects, by minimizing changes in experimental paradigms while the model organism is changed.

Imaging for clinical studies

Several questions need to be answered during the clinical stages of drug development. Foremost among these are the safety and efficacy profiles of the drug, but additional considerations should include the pharmacokinetic (PK) behavior of the drug, the appropriate dosing regimen and the degree to which supportive data can be obtained for regulatory approval. Imaging can potentially address each of these questions.

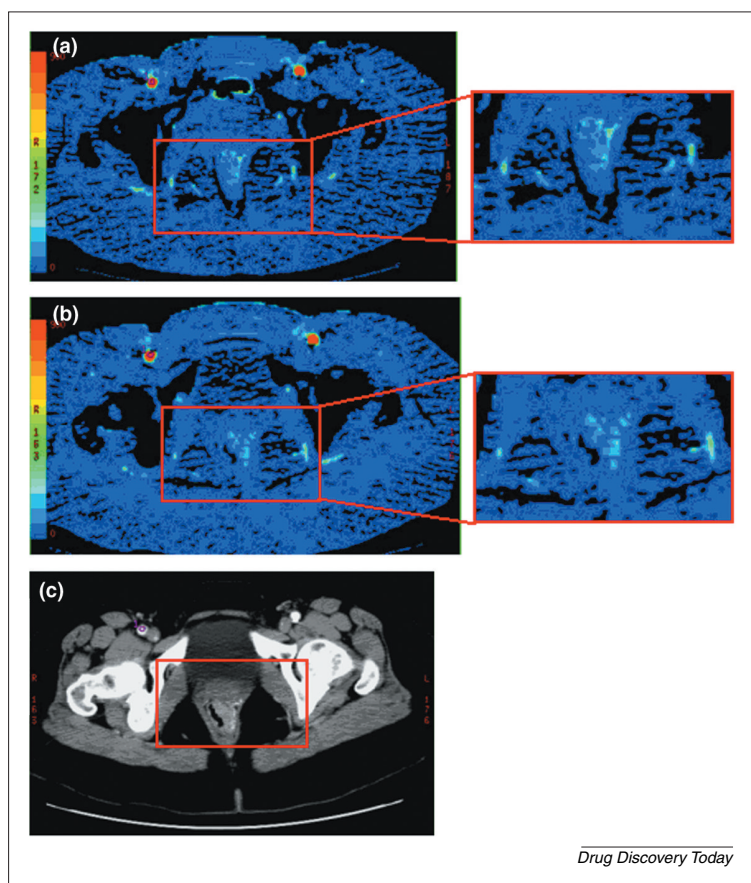


FIGURE 1
Computed tomography images from a 56-year old female patient with rectal tumors, before and 12 days after a single dose of bevacizumab. (a) Pre-treatment CT perfusion image showing an average blood flow rate within the tumor of 70 ± 15 $\text{ml } 100\text{g}^{-1} \text{min}^{-1}$. The pseudo-coloring of flow is shown on the intensity scale on the left. **(b)** Post-treatment CT perfusion image showing an average flow of 40 ± 16 $\text{ml } 100\text{g}^{-1} \text{min}^{-1}$. **(c)** Corresponding post-treatment CT axial image showing the anatomy surrounding the region of interest. Abbreviations: CT, computed tomography. Images courtesy of D. Sahani and S. Kalva of MGH.

Bioactivity indicators

The ability to obtain early indications of a drug's bioactivity is highly desirable. In the case of cancer therapeutics, for example, earlier indications might reduce a patient's exposure to ineffective, poorly tolerated, toxic or expensive treatments [31]. Conversely, lack of bioactivity could represent sufficient cause for suspension or termination of further R&D on unpromising compounds.

Imatinib mesylate (Gleevec, Novartis) is a tyrosine kinase inhibitor that has gained FDA approval for chronic myelogenous leukemia [32] and gastrointestinal stromal tumors (GIST). When using more-traditional methods, such as CT imaging for determining tumor size, to evaluate the effectiveness of imatinib on GIST, the first objective evaluation of tumor response is generally performed no earlier than two to three months after the start of treatment because earlier changes in tumor size are seldom significant [31]. Using FDG-PET as an indicator of tumor metabolism, however, it was found that reduction in glucose metabolism preceded CT response by a median of seven weeks, and

all GIST patients with a complete or major metabolic response subsequently reached partial or durable stable disease on CT [31].

In another cancer example, the overexpression of vascular endothelial growth factor (VEGF) is frequently implicated in tumor angiogenesis [33]. In one trial of the VEGF-specific monoclonal antibody bevacizumab (Avastin, Genentech) on rectal cancer patients, CT measurements of tumor blood flow and blood volume decreased significantly twelve days after a single infusion of the drug (Figure 1) [34]. This observed decrease in tumor perfusion demonstrated a positive correlation with other tumor indicators, including microvessel density, interstitial fluid pressure, and circulating endothelial and progenitor cell levels [34].

Other examples of early bioactivity assessment are available in the literature, including: (i) MRI for monitoring multiple sclerosis (MS) treatment [35]; (ii) MRI, CT and PET for assessing tumor angiogenesis [36–39]; (iii) functional MRI and CT for examining ischemic stroke [40,41]; (iv) MRI and PET for characterizing Alzheimer's disease [42]; and (v) various imaging techniques for assessing cardiovascular disease [43].

Pharmacokinetics and dosing

Numerous past studies have shown that it is possible to derive the PK distribution of radiolabeled pharmaceuticals using PET imaging [44,45]. In broad terms, imaging of PK properties falls into two categories. The first category involves the radiolabeling of compounds that interact with, or neutralize, agents from the environment, such as toxins, bacteria and viruses. In this case, generally only tissue concentrations of drugs are necessary. In the second category, if the drug is expected to alter or otherwise modulate some aspect of the pathophysiologic process, then imaging studies are generally used to characterize the number of receptors, binding efficiency and receptor occupancy.

As an example of the first category, the development of ^{18}F -labeled antifungal agent fluconazole (Diflucan, Pfizer) was monitored by PET to establish the concentration of the drug in different organs, particularly at the site of infection (Figure 2). The imaging study found that the observed concentrations compared favorably to the concentrations required to inhibit *in vitro* pathogen growth and provided valuable dosing information [46].

PET imaging of aprepitant (Emend, Merck) forms the basis of PK imaging of the second category. Aprepitant is a neurokinin-1 (NK-1) receptor antagonist that crosses the blood-brain barrier and was developed as, among other things, a treatment for emetogenic chemotherapy-induced nausea and vomiting [47]. By using a ^{18}F -labeled ligand with known high affinity and specificity for the NK-1 receptor, PET was used to image the displacement of this radioligand by aprepitant. During the clinical trial, because NK-1 receptors have been found to be most abundant in the caudate and putamen, and least abundant in the cerebellum, this information was used to establish a reference

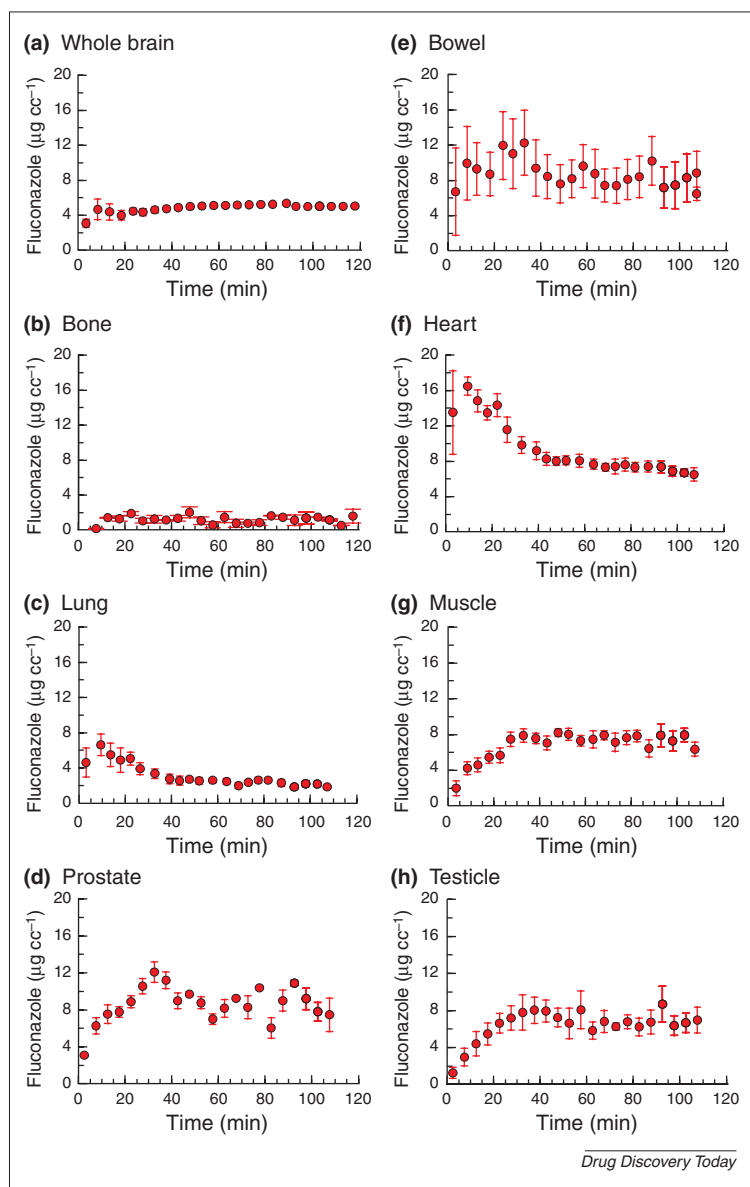


FIGURE 2

In vivo pharmacokinetic profiles of the antifungal drug fluconazole.

A radiolabeled version of the antifungal drug fluconazole (^{18}F -fluconazole) and PET imaging was used to produce a pharmacokinetic profile of the drug in eight regions of the body over a period of approximately two hours, as follows: (a) whole brain; (b) bone; (c) lung; (d) prostate; (e) bowel; (f) heart; (g) muscle; and (h) testicle. Six healthy subjects were tested to determine an average. Abbreviations: PET, positron emissions tomography. Figure reproduced, with permission, from Ref. [66].

and, subsequently, to compute the displacement of the PET tracer. In the final analysis, the imaging study established the receptor occupancy by the drug as a function of its plasma concentration [47].

Fischman has reviewed several examples of PK imaging of drugs for antifungal, antimicrobial and antineoplastic, in addition to those that modulate dopamine, serotonin, benzodiazepine, opioid and acetylcholine receptors [10]. The successes of such PK studies have led some researchers to pursue the use of imaging techniques to establish dosing regimens (see, for example, Ref. [48]). The high sensitivity of PET imaging has led several groups to consider micro-

dosing (the administration of minute quantities of drugs labeled with PET tracers) as a method of establishing and monitoring drug PK and safety profiles [30]. It is noteworthy that imaging modalities other than PET can be used to evaluate dosing regimens: MRI was recently used to evaluate drug regimens for interferon- β (IFN- β) treatments of MS [49], infliximab (Remicade, Centocor) for psoriatic arthritis [50], and PTK787 for colorectal cancer [51].

In contrast to previous examples in which early indications of bioactivity provides confidence in the use of the drug, the lack of proper bioactivity or pharmacodynamic-pharmacokinetic (PD-PK) profiles can help to terminate unpromising drug development efforts. One example is BMS181101, an antidepressant that was believed to be a potent inhibitor of 5-hydroxytryptamine (5-HT) receptors. By radiolabeling the compound with ^{11}C , cerebral PK imaging of the compound was examined using PET. Statistical comparisons of the compound's distribution to various regions of the brain showed no difference between high and low concentrations of the drug, suggesting the lack of specific receptor-binding [52]. The development effort was subsequently terminated.

Although it is appealing to believe that non-invasive PK profiling could permit the determination of Phase II dosing regimen on biological activity instead of toxicity, this has not been found to be the case. In an examination of 60 Phase I solid tumor drug trials, only one instance of imaging-based dose determination was found [53].

Phenotypic screening and prognostic indicators

The use of FDG-PET as an early indicator of bioactivity in anti-cancer treatments has already been described. One logical extension to this use of FDG-PET is to separate – as early as possible – responders from non-responders in patients undergoing therapeutic intervention. In one study examining advanced non-small-cell lung cancer, 55 patients were imaged with FDG-PET after a single course of chemotherapy. The results showed a statistically significant difference both in time to progression and overall survival between responders (i.e. those with observed decrease in tumor metabolism as seen on PET) and non-responders [54]. In another study involving 22 breast tumor patients, responders after a single course of chemotherapy were identified using FDG-PET with 100% sensitivity and 85% specificity, a result that is more accurate than predicting responders using histopathological response [55]. Similarly, in a study involving 40 gastroesophageal cancer patients, FDG-PET segregated responders from non-responders with a sensitivity of 93% and specificity of 95% [56]. Collectively, these studies suggest that cancer patients might be able to undergo transition to second-line therapies or consider surgical interventions much earlier, while minimizing the morbidity and costs associated with ineffective therapies.

Another illustration of the prognostic value of imaging is MRI for ischemic stroke. MR diffusion and perfusion

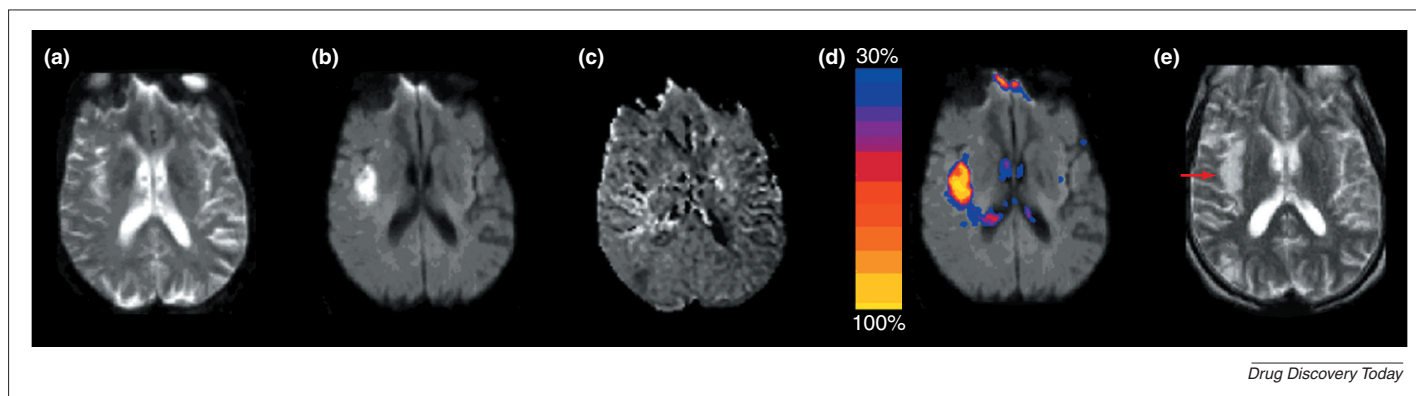


FIGURE 3

Stroke infarct prediction from ischemic stroke. Acute imaging taken at the time of a patient's initial visit to the emergency room: (a) T_2 -weighted echo-planar MR image; (b) diffusion-weighted MR image showing cellular abnormalities on the left side of the image; and (c) mean transit-time MR imaging, showing perfusion surrounding the location of the diffusion lesion. (d) The computed risk map based on acute imaging, showing the probability of infarction (indicated on the intensity scale, where 30% is low risk of infarction and 100% is high risk). (e) The agreement between predicted probabilities and the final outcome is shown in the six-day follow-up MR image. The red arrow indicates the location of the final infarct. Abbreviations: MR, magnetic resonance; T_2 , transverse relaxation time.

imaging have long been known to act as sensitive indicators of stroke, providing much earlier indicators of stroke location than T_2 imaging [57,58]. More recently, combinations of different representations of diffusion and perfusion were systematically analyzed (Figure 3) and, to date, numerous studies have shown the ability to use such combined measures as predictors of brain tissue at risk of infarction [41,59–61].

Devising accurate means of predicting outcome is an important element of pharmaco-imaging, with prognostic accuracy comes the potential for using each patient as his or her own control, allowing researchers to see the effect without and with interventions with less variability. Accurate prognosis can also provide a means of patient selection if only subjects with specific probable outcomes are desired in a clinical trial.

Regulatory registration

Imaging can frequently provide crucial supportive data for regulatory approval. Etanercept (Enbrel, Immunex, now Amgen), for example, is a tumor necrosis factor (TNF) inhibitor for the treatment of rheumatoid arthritis. When examining the potential for etanercept as a first-line treatment, early trials used two sets of criteria: (i) American College of Rheumatology (ACR) scores, which use a combination of subjective pain and function assessments, in addition to serum C-reactive protein levels; and (ii) conventional radiography images of joint-space narrowing and erosion. Whereas clinical scoring showed no significant difference between etanercept and methotrexate (the standard therapy at the time), the imaging-based erosion score showed statistically significant differences [62]. On the basis of these data, the FDA granted Immunex marketing approval with the condition that additional supporting data be collected. A subsequent study was able to show that etanercept achieved sustained improvements over methotrexate in terms of both clinical and imaging scores [63], thus gaining first-line treatment status.

MS is a complex disease with several treatment options available in the USA, including disease-modifying agents IFN- β -1a (Rebif, Serono; Avonex, Biogen) and IFN- β -1b (Betaseron, Berlex) for treating relapsing-remitting MS. Despite these successes, clinical trials for MS raise several issues, such as ethical concerns associated with conducting long-term placebo trials, and the size and cost of trials comparing new therapies with existing pharmaceuticals. As such, there has been greater reliance on imaging data in the conduct of these clinical trials, especially using T_2 -MRI lesion burdens (i.e. lesion number and load), in addition to the number of contrast-enhancing lesions. Within the US regulatory process, the FDA permits the use of biomarkers provided that such biomarkers are reasonably likely to predict future clinical outcome. As such, because of inconsistent correlations between T_2 lesion burden and contrast-enhancing lesion frequency to clinical scores, these imaging biomarkers can serve as primary outcome measure in exploratory trials (i.e. Phase I and Phase II), but can only serve as secondary outcome in pivotal trials [64]. Despite this reluctance to over-emphasize the importance of imaging, a recent trial with MS patients on IFN- β -1b treatment showed marked improvements in various imaging biomarkers over a three-year period [65]. Finally, it is noteworthy that MRI findings have sometimes been given less importance in the European Community than that in the USA [64].

Final remarks

Drug development is a complex, costly and risky venture. Evidence has now been accumulated, pointing to the potential role of imaging in mitigating risk and cost during drug development and clinical trials by validating targets, confirming mechanism of action, obtaining early indicators of bioactivity, assessing PK profiles, providing prognostic indicators and supporting regulatory filings. Yet, despite such promise, it is important to keep in mind the confounding factors that could mislead surrogates and

the degree to which biomarkers are validated for their intended purposes.

To impact drug development in a lasting, significant and pervasive fashion, however, we believe that two major advances must occur. First, pharmaco-imaging needs to evolve from a research endeavor to a high-throughput production system, which requires the integration of multiple-imaging modalities, as well as cellular, pre-clinical and clinical imaging. Second, the issue of validation of new imaging biomarkers needs to be addressed in a more systematic and rigorous way, including establishing correlations among imaging and molecular biomarkers, elucidating the relationship between particular imaging biomarkers and the purported pathophysiological pathways, promoting standards among image-acquisition protocols, and providing statistical assessments of the significance of particular imaging biomarkers in the context of specific diseases.

With recent advances in genomic, proteomic, imaging

and computational sciences, we believe the time is right for pharmaco-imaging to become an important tool in drug development. As a small first step, we have tabulated several hundred imaging biomarkers on our website (see: <http://www.biomarkers.org>). We strongly encourage the broader academic, clinical, industrial and government communities to join forces and explore the potential for using imaging to improve translational research and to significantly reduce the time and costs of developing new pharmaceuticals.

Acknowledgements

We thank Jerry Collins (FDA) and John Smith (Med-Tel International) for many thoughtful and insightful discussions. We also thank Dushyant Sahani and Sanjeeva Kalva (MGH) for providing the CT perfusion examples, and Janet Miller (MGH) for proofreading earlier drafts of this manuscript.

References

- DiMasi, J.A. et al. (2003) The price of innovation: new estimates of drug development costs. *J. Health Econ.* 22, 151–185
- Frank, R. and Hargreaves, R. (2003) Clinical biomarkers in drug discovery and development. *Nat. Rev. Drug Discov.* 2, 566–580
- FDA (2004) *Innovation or Stagnation? Challenge and Opportunity on the Critical Path to New Medical Products*, United States Food and Drug Administration
- DiMasi, J.A. (2002) The value of improving the productivity of the drug development process: faster times and better decisions. *Pharmacoeconomics* 20 (Suppl. 3), 1–10
- Merrill, R.A. (1996) The architecture of government regulation of medical products. *Va. Law. Rev.* 82, 1753–1866
- Johnson, J.R. et al. (2003) End points and United States Food and Drug Administration approval of oncology drugs. *J. Clin. Oncol.* 21, 1404–1411
- Congress U.S. (1997) *Food and Drug Administration Modernization Act of 1997*. Public Law 105–115, 1997. 105th Congress
- Beckmann, N. et al. (2004) Magnetic resonance imaging in drug discovery: lessons from disease areas. *Drug Discov. Today* 9, 35–42
- Rudin, M. et al. (1999) In vivo magnetic resonance methods in pharmaceutical research: current status and perspectives. *NMR Biomed.* 12, 69–97
- Fischman, A.J. et al. (2002) Pharmacokinetic imaging: a noninvasive method for determining drug distribution and action. *Clin. Pharmacokinet.* 41, 581–602
- Gambhir, S.S. (2002) Molecular imaging of cancer with positron emission tomography. *Nat. Rev. Cancer* 2, 683–693
- Grainger, R.G. et al. (eds) (2001) *Grainger & Allison's Diagnostic Radiology* (4th edn), Churchill Livingstone
- McRobbie, D.W. et al. (2002) *MRI from Picture to Proton*, Cambridge University Press
- Le Bihan, D. ed. (1995) *Diffusion and Perfusion Magnetic Resonance Imaging: Applications to Functional MRI*, Raven Press
- Sorensen, A.G. and Reimer, P. (2000) *Cerebral MR Perfusion Imaging: Principles and Current Applications*, Thieme
- Salibi, N. and Brown, M.A. (1998) *Clinical MR Spectroscopy*, Wiley
- Townsend, D.W. (2004) Physical principles and technology of clinical PET imaging. *Ann. Acad. Med. Singapore* 33, 133–145
- Echt, D.S. et al. (1991) Mortality and morbidity in patients receiving encainide, flecainide, or placebo. The Cardiac Arrhythmia Suppression Trial. *N. Engl. J. Med.* 324, 781–788
- Fleming, T.R. and DeMets, D.L. (1996) Surrogate end points in clinical trials: are we being misled? *Ann. Intern. Med.* 125, 605–613
- Temple, R. (1999) Are surrogate markers adequate to assess cardiovascular disease drugs? *JAMA* 282, 790–795
- Buyse, M. et al. (2000) Relation between tumour response to first-line chemotherapy and survival in advanced colorectal cancer: a meta-analysis. Meta-Analysis Group in Cancer. *Lancet* 356, 373–378
- Weissleder, R. (2002) Scaling down imaging: molecular mapping of cancer in mice. *Nat. Rev. Cancer* 2, 11–18
- Weissleder, R. and Ntziachristos, V. (2003) Shedding light onto live molecular targets. *Nat. Med.* 9, 123–128
- Pomper, M.G. (2002) Can small animal imaging accelerate drug development? *J. Cell. Biochem. Suppl.* 39, 211–220
- Smith, G.S. et al. (2003) Applications of neuroreceptor imaging to psychiatry research. *Psychopharmacol. Bull.* 37, 26–65
- Herschman, H.R. (2003) Molecular imaging: looking at problems, seeing solutions. *Science* 302, 605–608
- Beckmann, N. et al. (2001) From anatomy to the target: contributions of magnetic resonance imaging to preclinical pharmaceutical research. *Anat. Rec.* 265, 85–100
- Mack, W.J. et al. (2003) Serial magnetic resonance imaging in experimental primate stroke: validation of MRI for pre-clinical cerebroprotective trials. *Neurol. Res.* 25, 846–852
- Duyk, G. (2003) Attrition and translation. *Science* 302, 603–605
- Bergstrom, M. et al. (2003) Positron emission tomography microdosing: a new concept with application in tracer and early clinical drug development. *Eur. J. Clin. Pharmacol.* 59, 357–366
- Stroobants, S. et al. (2003) 18FDG-Positron emission tomography for the early prediction of response in advanced soft tissue sarcoma treated with imatinib mesylate (Glivec). *Eur. J. Cancer* 39, 2012–2020
- Capdeville, R. et al. (2002) Glivec (STI571, imatinib), a rationally developed, targeted anticancer drug. *Nat. Rev. Drug Discov.* 1, 493–502
- Kerbel, R. and Folkman, J. (2002) Clinical translation of angiogenesis inhibitors. *Nat. Rev. Cancer* 2, 727–739
- Willett, C.G. et al. (2004) Direct evidence that the VEGF-specific antibody bevacizumab has antivasular effects in human rectal cancer. *Nat. Med.* 10, 145–147
- Rao, A.B. et al. (2002) Methylprednisolone effect on brain volume and enhancing lesions in MS before and during IFNbeta-1b. *Neurology* 59, 688–694
- Neeman, M. and Dafni, H. (2003) Structural, functional, and molecular MR imaging of the microvasculature. *Annu. Rev. Biomed. Eng.* 5, 29–56
- Morgan, B. et al. (2003) Dynamic contrast-enhanced magnetic resonance imaging as a biomarker for the pharmacological response of PTK787/ZK 222584, an inhibitor of the vascular endothelial growth factor receptor tyrosine kinases, in patients with advanced colorectal cancer and liver metastases: results from two phase I studies. *J. Clin. Oncol.* 21, 3955–3964
- Miles, K.A. (2002) Functional computed tomography in oncology. *Eur. J. Cancer* 38, 2079–2084
- Davis, D.W. et al. (2003) Surrogate markers in antiangiogenesis clinical trials. *Br. J. Cancer* 89, 8–14
- Provenzale, J.M. et al. (2003) Assessment of the patient with hyperacute stroke: imaging and therapy. *Radiology* 229, 347–359
- Wu, O. et al. (2001) Predicting tissue outcome in acute human cerebral ischemia using combined diffusion- and perfusion-weighted MR imaging. *Stroke* 32, 933–942

- 42 Cummings, J.L. (2004) Alzheimer's disease. *N. Engl. J. Med.* 351, 56–67
- 43 Rajaram, V. *et al.* (2004) Role of surrogate markers in assessing patients with diabetes mellitus and the metabolic syndrome and in evaluating lipid-lowering therapy. *Am. J. Cardiol.* 93, 32C–48C
- 44 Fischman, A.J. *et al.* (1991) Pharmacokinetics of 18F-labeled fluconazole in rabbits with *Candida* infections studied with positron emission tomography. *J. Pharmacol. Exp. Ther.* 259, 1351–1359
- 45 Parsey, R.V. *et al.* (2000) Validation and reproducibility of measurement of 5-HT_{1A} receptor parameters with [carbonyl-11C]WAY-100635 in humans: comparison of arterial and reference tissue input functions. *J. Cereb. Blood Flow Metab.* 20, 1111–1133
- 46 Fischman, A.J. *et al.* (1993) Pharmacokinetics of 18F-labeled fluconazole in healthy human subjects by positron emission tomography. *Antimicrob. Agents Chemother.* 37, 1270–1277
- 47 Bergstrom, M. *et al.* (2004) Human positron emission tomography studies of brain neurokinin 1 receptor occupancy by aprepitant. *Biol. Psychiatry* 55, 1007–1012
- 48 Mamo, D. *et al.* (2004) EMD 281014, a specific and potent 5HT₂ antagonist in humans: a dose-finding PET study. *Psychopharmacology (Berl.)* DOI: 10.1007/s00213-004-1817-7 (www.springerlink.com)
- 49 Durelli, L. (2003) Dose and frequency of interferon treatment matter—INCOMIN and OPTIMS. *J. Neurol.* 250 (Suppl. 4), IV9–IV14
- 50 Antoni, C. *et al.* (2002) Open-label study of infliximab treatment for psoriatic arthritis: clinical and magnetic resonance imaging measurements of reduction of inflammation. *Arthritis Rheum.* 47, 506–512
- 51 Thomas, A.L. *et al.* (2003) Vascular endothelial growth factor receptor tyrosine kinase inhibitors: PTK787/ZK 222584. *Semin. Oncol.* 30, 32–38
- 52 Christian, B.T. *et al.* (1996) Evaluation of cerebral pharmacokinetics of the novel antidepressant drug, BMS-181101, by positron emission tomography. *J. Pharmacol. Exp. Ther.* 279, 325–331
- 53 Parulekar, W.R. and Eisenhauer, E.A. (2004) Phase I trial design for solid tumor studies of targeted, non-cytotoxic agents: theory and practice. *J. Natl. Cancer Inst.* 96, 990–997
- 54 Weber, W.A. *et al.* (2003) Positron emission tomography in non-small-cell lung cancer: prediction of response to chemotherapy by quantitative assessment of glucose use. *J. Clin. Oncol.* 21, 2651–2657
- 55 Schelling, M. *et al.* (2000) Positron emission tomography using [(18)F]Fluorodeoxyglucose for monitoring primary chemotherapy in breast cancer. *J. Clin. Oncol.* 18, 1689–1695
- 56 Weber, W.A. *et al.* (2001) Prediction of response to preoperative chemotherapy in adenocarcinomas of the esophagogastric junction by metabolic imaging. *J. Clin. Oncol.* 19, 3058–3065
- 57 Kucharczyk, J. *et al.* (1991) In vivo diffusion-perfusion magnetic resonance imaging of acute cerebral ischemia. *Can. J. Physiol. Pharmacol.* 69, 1719–1725
- 58 Warach, S. *et al.* (1992) Fast magnetic resonance diffusion-weighted imaging of acute human stroke. *Neurology* 42, 1717–1723
- 59 Sorensen, A.G. *et al.* (1999) Hyperacute stroke: simultaneous measurement of relative cerebral blood volume, relative cerebral blood flow, and mean tissue transit time. *Radiology* 210, 519–527
- 60 Grandin, C.B. *et al.* (2001) Usefulness of magnetic resonance-derived quantitative measurements of cerebral blood flow and volume in prediction of infarct growth in hyperacute stroke. *Stroke* 32, 1147–1153
- 61 Schaefer, P.W. *et al.* (2002) Predicting cerebral ischemic infarct volume with diffusion and perfusion MR imaging. *AJNR Am. J. Neuroradiol.* 23, 1785–1794
- 62 Bathon, J.M. *et al.* (2000) A comparison of etanercept and methotrexate in patients with early rheumatoid arthritis. *N. Engl. J. Med.* 343, 1586–1593
- 63 Genovese, M.C. *et al.* (2002) Etanercept versus methotrexate in patients with early rheumatoid arthritis: two-year radiographic and clinical outcomes. *Arthritis Rheum.* 46, 1443–1450
- 64 McFarland, H.F. *et al.* (2002) The role of MRI as a surrogate outcome measure in multiple sclerosis. *Mult. Scler.* 8, 40–51
- 65 Frank, J.A. *et al.* (2004) Interferon-beta-1b slows progression of atrophy in RRMS: Three-year follow-up in NAb- and NAb+ patients. *Neurology* 62, 719–725
- 66 Fischman, A.J. *et al.* (1997) The role of positron emission tomography in pharmacokinetic analysis. *Drug Metab. Rev.* 29, 923–956

Related articles in other Elsevier journals

Fluorescence techniques for drug delivery research: theory and practice

White, N.S. and Errington, R.J. (2005) *Adv. Drug Deliv. Rev.* 57, 17–42

Magnetic resonance imaging in drug discovery: lessons from disease areas

Beckmann, N. *et al.* (2004) *Drug Discov. Today* 9, 35–42

Biomarker discovery and validation: technologies and integrative approaches

Ilyin, S.E. *et al.* (2004) *Trends Biotech.* 22, 411–416

Assessment of neuroimaging techniques as biomarkers of the progression of Parkinson's disease

Brooks, D.J. *et al.* (2003) *Exp. Neurol.* 184, 68–79